Ann. For. Res. 65(1): 1820-1839, 2022
ISSN: 18448135, 20652445

ANNALS OF FOREST RESEARCH
https://www.e-afr.org/

A SURVEY ON IDENTIFICATION OF DIABETIC RETINOPATHY FOR MEDICAL DIAGNOSIS

G.Indira Devi
Electronics and Communication Engineering, Anil Neerukonda Instistute of Science and Technology, Visakhapatnam, India, gedela.indira@gmail.com

D.Madhavi
Department of ECE, GIT, GITAM University, Visakhapatnam,India
mdunna@gitam.edu

Abstract
Diabetic retinopathy is a complication of diabetes, which causes damage to the retina as well as other very small blood vessels located throughout the body (DR). Deterioration in the development of the retina is one of the symptoms that may be seen with this condition. There is an increased risk of being completely blind as diabetic retinopathy worsens over time. In light of the aforementioned circumstances, it is more important than ever before to perform an early diagnosis of diabetes and diabetic retinopathy in order to identify the damaged lesions and offer the diabetic patients with the appropriate counseling and therapy. DR may be identified by hand or automatically, depending on your preference. Both strategies might be considered viable options. Optometrists and ophthalmologists are the ones who actually do the manual operation; they are also the ones who give evaluations and reasons for it. It takes a significant amount of time, and expensive equipment is necessary. Automated systems that use artificial intelligence and deep learning rather than more traditional methods would be able to recognise DR at an earlier stage of the automation problem. The bulk of the research that has been conducted has focused on the importance of diagnosing DR at an early stage. This article gives an overview of automated DR detection techniques by focusing on two essential properties of fundus pictures and DR detection strategies. Both of these topics are discussed in the essay. The following constitutes each of these components: This article describes a number of challenges that aspiring academics face, as well as the discoveries that were made by those who came before them.

Keywords: Diabetic Retinopathy, Fundus Images, Retinal Imaging, Optical Disk, Blood Vessels, Exudates

1.Introduction

Diabetes is a disease that impacts a significant number of individuals all over the globe. It is the leading cause of blindness in those under the age of 50 in an overwhelming majority of instances. A systemic ailment has been present in up to eighty percent of patients for more than ten years. According to a significant amount of data, early detection may allow ninety percent of diabetes patients to live longer than they would otherwise. [Citation needed] Diabetic retinopathy, often known as diabetic retinopathy (DR), is a condition that may occur in people who have diabetes [1.

All of the layers of the retina get their blood supply via very small blood capillaries, which are susceptible to injury when exposed to high amounts of glucose in the blood. Because there is a decrease in the amount of oxygen that is given to the cells when there is an abundance of glucose or fructose in the circulation, the arteries begin to degenerate. This is because there is a reduction in the amount of glucose or fructose in the circulation. If there is any blockage in these arteries, it will result in severe injury to the eye. This has the direct consequence of slowing down the metabolic rate, which in turn causes structural problems in the arteries that transport DR [2].

One of the first signs of DR is the presence of a microaneurysm. As a consequence of this illness, there is a possibility that the diameter of the blood vessels may change (swelling). Some of the indications of DR include microaneurysms (MAs), exudates (EXs), and haemorrhages (HMs), as well as abnormal blood vessel formation. There are two phases that are usually used to define the progression of DR [3]. These stages are known as proliferative DR (PDR) and non-proliferative DR (NPDR). When blood vessels in the retina get broken and start leaking fluid onto the retina, this is the first step in the process that leads to NPDR. Because of this, the retina has been directly impacted, and as a result, it has become moist and swollen. At this stage, several of the retinopathy symptoms, including HMs, MAs, EXs, and inter retinal micro vascular abnormalities, become visible. The pathological growth of new blood vessels in several locations of the retina is one of the defining characteristics of PDR. This complicated example of DR might potentially have an effect on the patient's eyesight [4]. Due to the fact that DR is a degenerative disorder, it is imperative to detect it in its earliest stages in order to preserve a patient's vision. For this purpose, regular surveillance is required. By using an automated screening method, there is a possibility that not only would the workload of ophthalmologists be reduced, but there would also be a reduction in the risk of developing complete blindness as a result of diabetic retinopathy. Currently, work is being done to create a computer-aided diagnostic (CAD) system with the intention of using it for the screening of DR [5-7]. This method will be able to differentiate between a normal retina and a retina that may be affected by DR.
When there is an excessive amount of sugar in the blood, the tiny blood vessels that supply the retina with blood run the risk of becoming clogged, which will eventually cut off the blood supply to the retina. This can result in vision loss. As a direct consequence of this, the eye will attempt to generate brand new blood vessels. Because of the inefficient manner in which these newly formed blood vessels were created, they are susceptible to developing leaks. There are two main manifestations that diabetic retinopathy can take[8]:

- **Early diabetic retinopathy.** This more prevalent form of diabetic retinopathy, also known as non-proliferative diabetic retinopathy or NPDR for short, is distinguished by the absence of the formation of new blood vessels (proliferating). The degeneration of the walls of the retinal blood vessels is one of the distinctive characteristics of NPDR. When this takes place, there is a possibility that fluid and blood will be able to penetrate the retina via minute bulges that protrude from the vessel walls of smaller blood vessels. If the condition is not treated, bigger vessels in the retina may begin to grow and have uneven widths. This

might lead to vision loss. When more blood arteries get clogged, the severity of NPDR may worsen from a moderate condition to a severe one. In very rare cases, damage to the blood vessels in the centre of the retina may lead to the creation of an edoema, also known as a fluid accumulation (macula). In the event that macular edoema is detectable, treatment is essential in order to forestall the development of visual impairment that is irreversible.

- **Advanced diabetic retinopathy.** This more serious form of diabetic retinopathy, sometimes referred to as proliferative diabetic retinopathy, is a possibility for diabetic patients. This kind of blood vessel injury that causes it to close off leads in the creation of new blood vessels in the retina that are not usual. Due to the fragility of the new blood vessels, there is a possibility that some of them may leak into the transparent jelly-like fluid that fills the centre of your eye (vitreous). Because the development of new blood vessels results in the formation of scar tissue, it is possible that your retina could eventually become detached from the retinal layer that is located at the rear of your eye. It is possible for pressure to build up within the eyeball if the new blood vessels prevent the eye from draining fluid in its natural manner. This accumulation, which causes damage to the nerve that sends pictures from your eye to your brain, has been linked to the development of glaucoma (optic nerve). The symptoms that are present at each phase of the DR are shown in Figure 1.

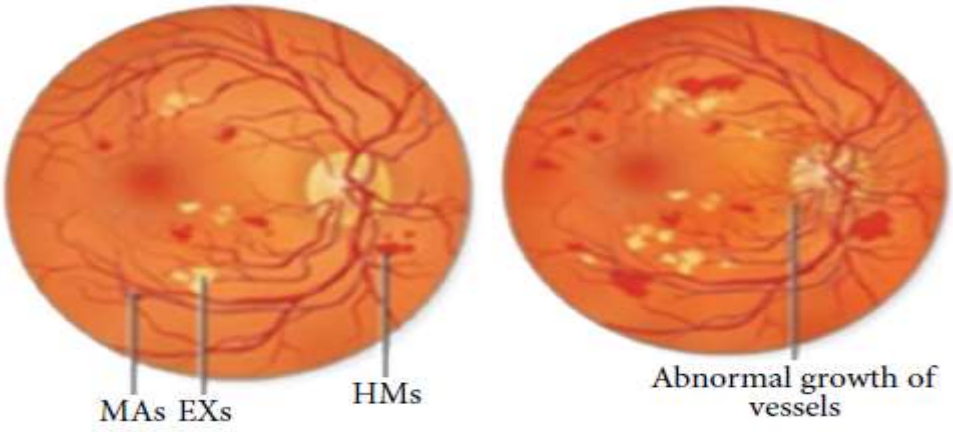

(a) Signs of NPDR (b) Sign of PDR

Figure1. Stage of DR

There are several different manual detection procedures that one may utilise in order to recognise the symptoms of diabetic retinopathy. A few examples of these are the visual acuity test, the tonometry examination, the dilated eye exam, and the fundus camera. The method that is used to evaluate both our visual acuity and our sight numbers is precisely the same. We could also be able to access the interior information if we do eye exams using dilated pupils and use eye drops that increase the thickness of the layer of tissue that lines the inside of the eye. In addition to the

many anomalies that are linked with diabetic retinopathy, a normal retina may also be shown in.

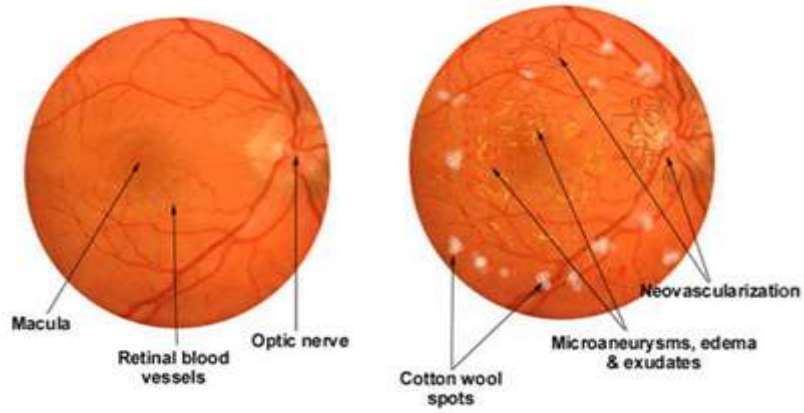

(a) (b)

Figure2. (a) Normal Retina (b) Diabetic Retina

2. Related Work

The International Clinical Diabetic Retinopathy (ICDR) scale is the mostly used clinical scales [9] and consists of 5-Point grade for Diabetic Retinopathy i.e. normal, mild, moderate, severe and proliferative. This categorization proposed by ICDR used by many AI algorithms to know the severity of Diabetic Retinopathy (DR).

Table1. Various type of DR with its lesions and symptoms

Symptoms	Type of DR
Lesions occur are micro-aneurysms, exudates and deep hemorrhages.	Background DR
Lesions occur are exudates and hemorrhages too	Pre-proliferative DR (Moderate NDPR)
Sign of micro-aneurysms	Mild NDPR
Intraretinalmicro-vascular abnormalities in one or more quadrant	Severe NDPR
Fibrous tissues arising from retina or optic disc	Proliferative DR

Lesions, which are afflicted portions of the retina, are examined to determine whether or not diabetic retinopathy is present in the patient. The terms haemorrhages, exudates, and microaneurysms are used, respectively, to characterise the lesions that have been affected by the condition. The following diagram, which has been given the designation of Figure3, is an illustration of the classification of DR according to the different kinds of lesions.

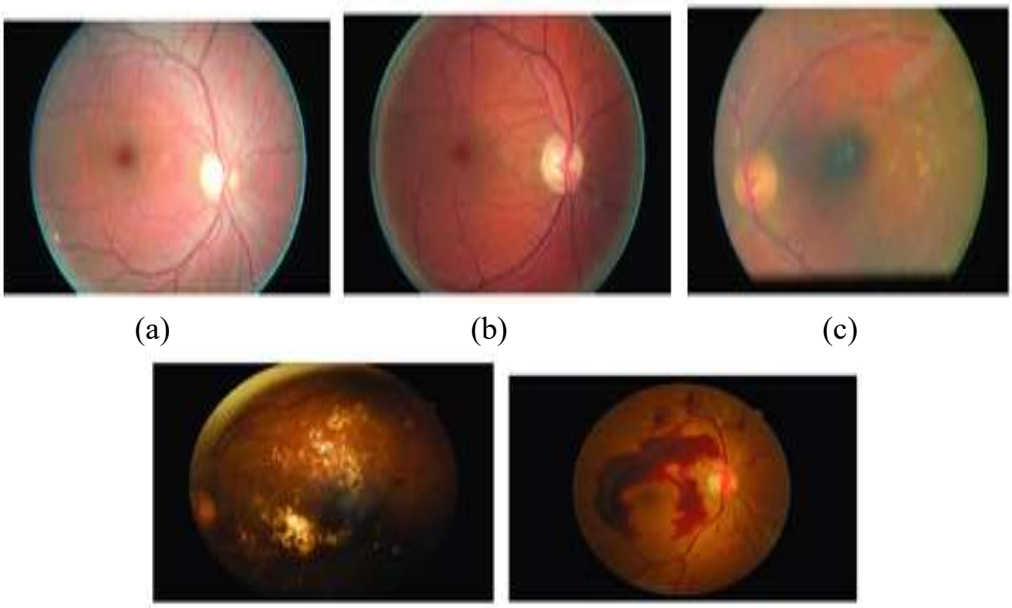

Figure3. Different stages of DR: (a) Normal retinal (b) Mild DR (c) Moderate DR (d) Severe DR (e) Proliferative DR.

This literature review's primary objective is to confirm the advancements achieved for the automated identification of diabetic retinopathy and DR lesions using both traditional methods and cutting-edge technologies such as deep learning and artificial intelligence. This is the primary objective of this review of the relevant scientific literature.

The main objectives of this research study are:

- Availability of publicly available datasets in study of detection of diabetic retinopathy.
- Different techniques used for detection of DR based on the features of retinal images.
- Performance assessment of DR detection algorithms.

Recent estimates suggest that India is home to more than 40 million people living with diabetes, the vast majority of whom get DR as a direct consequence of their condition. People who have DR have a ninety percent chance of surviving if they are diagnosed with the condition at an early stage. It is possible to put a halt to and recognise DR via the use of both manual and automated methods. A process that must be carried out manually consumes a significant amount of time. Ophthalmologists need to have a high level of expertise in their profession in order to be able to provide this treatment effectively. As a direct consequence of the breakthroughs made in ophthalmology, artificial intelligence is already giving the capabilities necessary to detect and cure essential disorders like diabetic retinopathy [10]. This is a direct outcome of the progress made in the field of ophthalmology. A technique for concurrently evaluating diabetic retinopathy (DR) and diabetic macular edoema (DME) was outlined in reference [11]. In this analysis, the researchers employed picture level supervision as a means of drawing attention to the inherent linkages that exist between these two diseases throughout disease attention networks [12]. The author of this piece presented CNN as an example of a news organisation that makes use of deep learning. The

process of semantic segmentation is used to differentiate between images of the retina that are in good health and those that are in poor health. This information may be used by ophthalmologists and opticians in order to classify the degree of NDPR in the images as mild, moderate, or severe [13].

The researcher presents a support vector machine model in the article [14] that takes use of four hundred fundus pictures taken from datasets that are available to the general public. The objective of the software is to isolate the various retinal lesions and determine automatically which group belongs to NDPR. In this study, 400 images taken from the Kaggle dataset were analysed using the HSV and V transform techniques in order to determine the presence of diabetic retinopathy. To increase the quality of these photographs, an approach to image enhancement was used. The author of this post [15] suggested employing a method known as a radial inverse force histogram in order to make image retrieval more efficient. [This phrase needs a reference] [This phrase needs a reference] [This phrase needs a reference] [This phrase needs a reference] [Reference needed This method may be used to identify as well as diagnose DR lesions. An approach to deep learning that is suitable for use with CNN was presented by the author of [16]. The linear support vector machine is used during the training process for the CNN. The SVM was able to differentiate between retinal fundus pictures that had DR and those that did not have DR. The author utilises the Eye PACS dataset in order to accomplish the goals of his research.

In the study that was referred to as [17], the researchers used automated procedures with the assistance of a Computer Assisted Diagnostic (CAD) system. When taking photos using optical coherence tomography (OCT), applying segmentation algorithms will make it possible to do automatic detection and categorization of the many forms of NDPR. This will be possible. An approach to DR detection that makes use of DCNN was developed by the author of [18]. The author of this piece decided to use fractional max pooling for the layers, as opposed to the max pooling layers that were used in the earlier post. These layers are trained using the Kaggle dataset, which is made accessible for the diagnosis of diabetic retinopathy, to portray the needed attributes. This enables the layers to accurately identify diabetic retinopathy. After combining all of the relevant criteria and data, the DCNNs and SVM classifier are used to assign grades to the various phases of the DR process. These grades are indicated by numerals that range from 0 to 4, inclusive. In addition, the researchers developed an app for smartphones called Ophthalmoscopes have deep retina implants. This software makes use of machine learning algorithms. Now that this method has been developed, members of the general public may look at their very own fundus photos.

In [19], the concept of an intense application known as a Deep CNN was proposed. Imaging in medicine is one of the applications of this technology. This result was accomplished by integrating the dataset from MESSIDOR with the publicly available dataset DR1. The following describes each of the three stages of this process: CNN layer-by-layer fine tuning, layer-by-layer fine tuning of trained CNN, and application of this to an SVM classifier after network characteristics have been extracted. All of these processes are performed in order. In the article [20], the author presents a method known as Multiple Instance Learning (MIL), the purpose of

which is to recognise DR and other associated diseases. Kaggle, Messidor, and DIARETDB1 are the three separate datasets that were used for this specific purpose. All of these datasets are open to the general public and may be accessed by anybody. In order to classify the various lesions brought on by diabetic retinopathy, the operation of extracting picture features from CNN was carried out, and the global aggression method was used. The developer of [21] produced a mobile application for smartphones that use a deep neural network to evaluate DR patients in real time, and they made the instrument available for download (DNN).

3. Datasets

This section describes the fundus image databases that may be available both publicly and privately in order to assist in the diagnosis of diabetic retinopathy. These databases may include images of the fundus, which is a part of the retina. Access to these datasets may be made public or kept private at the user's discretion. The datasets in question are sometimes referred to as benchmark or standard datasets. Anyone is free to utilize the datasets in question. Researchers make use of them in their work to further their investigations. The specifics of the study subject as well as the methodology that will be used in order to investigate it thoroughly will determine how these datasets will be put to use.

A. Kaggle

Kaggle dataset of retinal fundus images are most commonly used for the diagnosis of diabetic retinopathy. It was developed by EyePACS and made possible to use by researches for free. It consists of nearly 88902 retinal images, in which 35,126 images can be used for training and 53,576 images can be used for testing purpose [22].

B. DIARETDBI

DIARETDBI is one of publicly available dataset used for DR identification. This dataset contained 89 images. Five are normal fundus images, remaining 84 were assigned for DR [23].

C. DIARETDBO

DIARETDBO dataset is a well-known public dataset of retinal images used for DR detection. These are 130 images in DIARETDBO, out of which 110 were assigned with DR and remaining 20 were labeled as normal retinal image [24].

D. E-Ophtha

E-Ophtha dataset is a public dataset, used for finding retinal abnormalities and DR identification. This is available as two separate datasets labeled as E-ophtha MA, consists of 381 retinal images and E-ophtha Ex, consists of 82 images [25].

E. STARE

STARE dataset is a public dataset of retinal fundus images made by university of California, which contains 400 fundus photographs. These images are taken by the Topcon fundus camera [26].

F. DRIVE

DRIVE dataset is public dataset of retinal images, made by Holland for both education & research. It contains 40 images, non-mydriatic canon CR5 camera was used for taking thisphotograph. 20 images were assigned for training and 20 were used for testing purposes [27].

G. Messidor

It is a public dataset to find DR. Messidor – 2 retinal fundus images were taken by a non- mydriatic Topcon camera. It consists of 1784 images [28].

H. Retinopathy online challenge (ROC)

ROC dataset was developed by university of Iowa. Canon CR5-45 retinal digital fundus camera is used to capture images. It contains 100 retinal images. Half of the images were used for training and another half used for testing [29].

I. CHASE-DB1

CHASE-DB1 is also a publicly available dataset produced by Child health and study England (CHASE). This has taken retinal images from 14 children and prepared a dataset. It maintains 28 retinal images of children for both testing and training purposes [29].

J. FAZ (Foveal Avascular zone)

FAZ dataset contain 60 retinal images and publicly available. Out of 60 images, 25 images were normal retinal images and 35 images were categorized under DR images [30]

K. DR1& DR2

DR1 in also publicly available and it is produced by the federal university of Saopaulo. It contains total 234 retinal images [17]. DR2 is also provided by federal university of Saopaulo to facilitate researchers for free without any cost. It holds nearly 520 photographs of retina. These images are taken by non-mydriatic digital camera [31].

L. AR1A

AR1A dataset is a publicly available dataset and images taken by Zeiss FF450 fundus camera with 50 degrees field of view(FOV). This dataset contains totally 143 retinal fundus images [32].

4. Methods for Detection of DR

Diabetic Retinopathy is a disease characterized by the process of worse development of retina which causes the different types of organs suffered includes microaneurysms, intra retinal edema, hemorrhages etc.

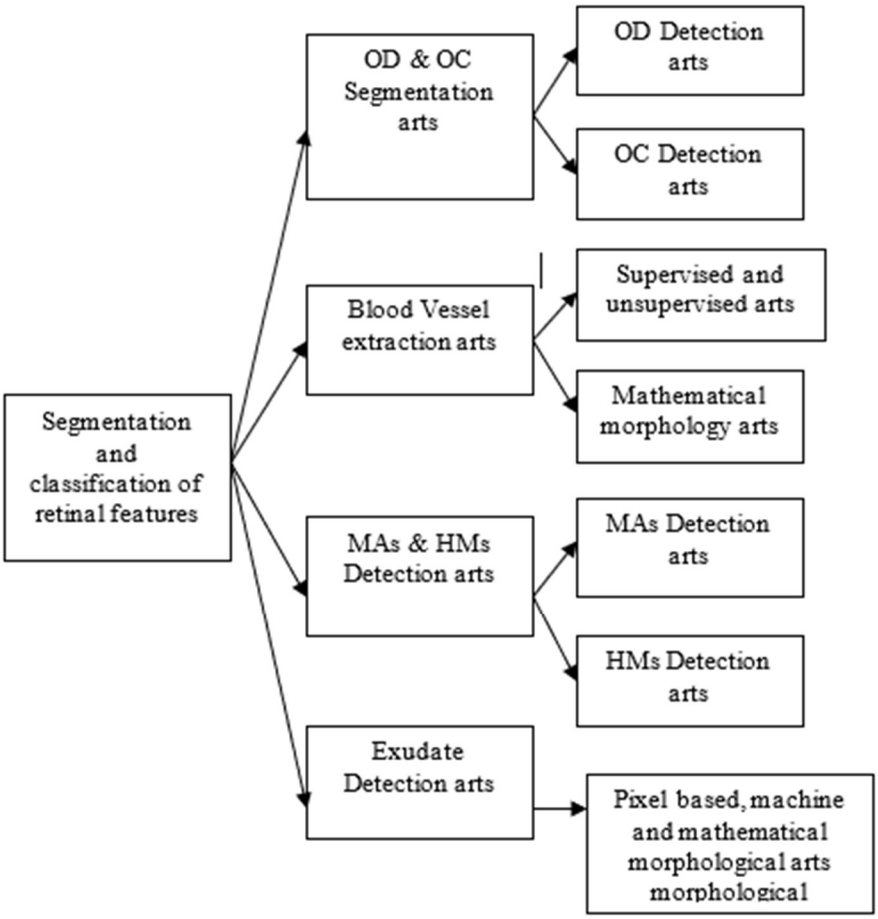

Figure4. Different methods for Identifying DR

These abnormalities are essential for determining the presence of diabetic retinopathy and making a diagnosis of the condition. In order to arrive at a diagnosis of diabetic retinopathy, a wide range of diagnostic methods were used, and retinal lesions were found to have been present (DR). The parts that follow will go through each individual portion in more detail. The enormous research that has been done on the detection of diabetic retinopathy lesions and the numerous segmentation methodologies has been broken down into several different parts. Figure 4 presents an overview of the several approaches to DR segmentation and detection that are currently available. These methods are broken down into their respective categories according to the many retinal lesions that might lead to DR.

A. Techniques of OD & OC Segmentation

Optic disc (OD) is treated as a preliminary stage of optic cup(OC), macula, fovea and vessel detection in the retinal images. In existing research, morphological and geometric arts were used for OD detection and machine learning and pixel-based arts were used for OC detection. Figure 4 gives the block diagram of OD and OC segmentation.

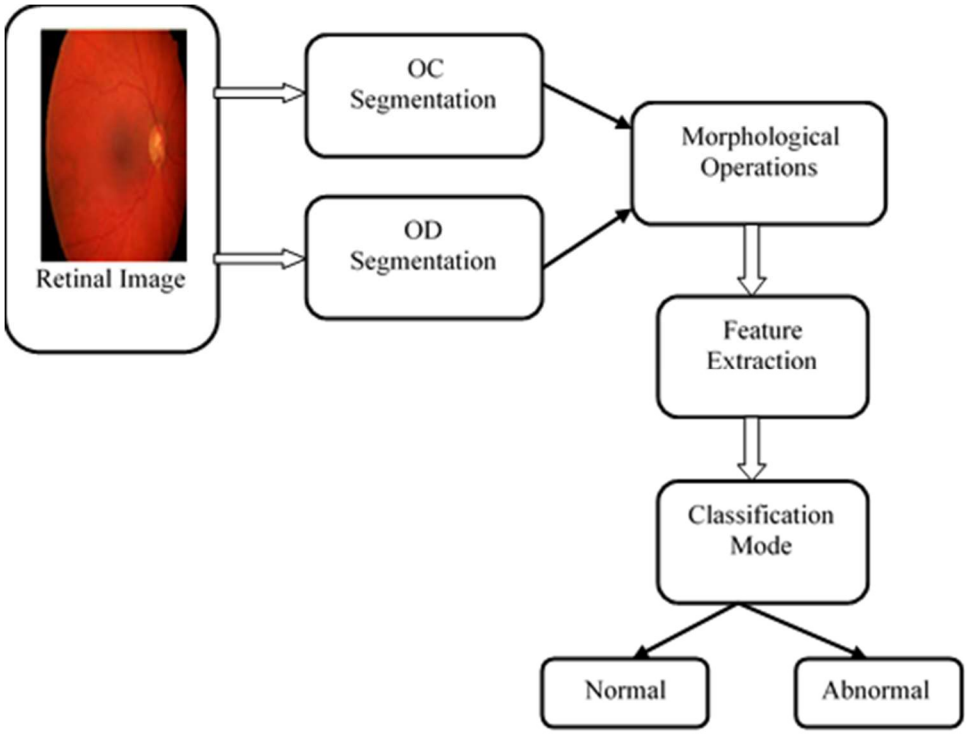

Figure 5. OD and OC segmentation

Non-proliferative diabetic retinopathy is another term that may be used interchangeably with pre-proliferative diabetic retinopathy (NDPR). In its earlier stages, the DR was once referred to as the NDPR. Within the scope of this NDPR, there are a total of three unique severity categories [33]. The author of "34" presented a method that may be used to make an automated diagnosis of organ damage. This method is comprised of four distinct procedures that need to be carried out in order for it to be successful. Pretreatment, the identification of any potential lesions, the extraction of vascular tissue, and the excision of the optic disc are the steps involved. The effectiveness of this detection approach may be attributed to the fact that it is not affected by the fact that the lesions may assume a variety of forms. The author of the article [35] described their suggested strategy, which could be broken down into three distinct processes, for locating and dividing up the optic disc. During the course of the preprocessing phases, the pictures of the retinal fundus will have their contrast and brightness boosted and fine-tuned as necessary. Morphological surgeries are performed with the intention of removing blood arteries. After that, the Circular Hough Transform was used in order to pinpoint the OD (CHT). A localized region-based active contour model is used for the purpose of performing the segmentation of the measured OD.

The author of the paper [36] developed a segmentation approach in order to determine the location of the origin pixel of the border vessel of the optical disc. In the first phase of this process, the green planes that can be seen in the fundus photos are scaled and morphologically rebuilt. This step is one of many that are involved. This method sheds light on the reasons behind why this is the case. After that, the image is reconstructed by dimming the bright parts of the picture that are in close proximity to the important blood veins. Using six region-based variables and a gaussian

mixer model classifier, the proposed technique categorizes optical density (OD) areas as either brighter OD regions or non-OD regions. The gaussian mixer model classifier is used. The distance that each extra viable location is located from the center of attention was a primary consideration in its selection. It was found that the position of the OD that had the highest vessel total and solidity as well as the brightest potential OD was the best possible choice for the OD. Figure 6 illustrates how the OD and OC work in their respective roles.

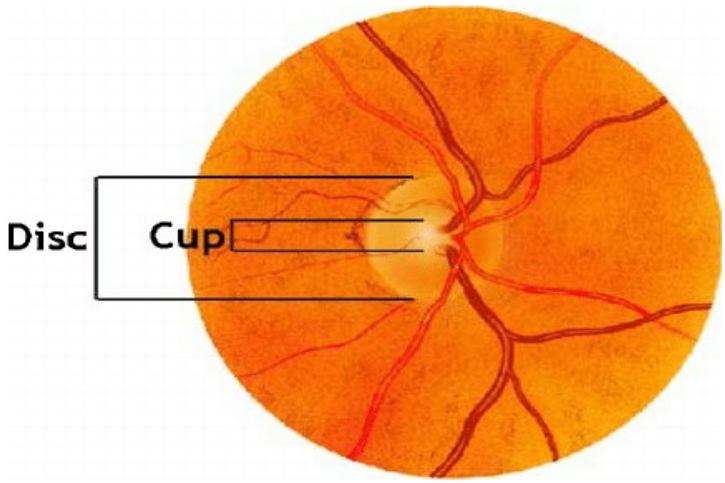

Figure 6. Demonstrates the optic disc and optic cup graphically

B. Techniques of blood vessel Segmentation

The correct segmentation of retinal blood vessels is a need for CAD systems that are used for the diagnosis and treatment of ophthalmological conditions. Ophthalmologists and opticians depend largely on the identification and segmentation of retinal blood vessels to diagnose various retinal illnesses and conditions, such as glaucoma, hypertension, and most importantly, diabetic retinopathy. The separation of the blood vessels in the retina is useful for a variety of other purposes as well, including the detection of the optic disc. Retinal photography allows for the identification of the fovea and the optic disc by determining where the blood vessels are located in the retina. The information that is collected from the retinal blood vessels may be used to help identify the severity of the DR, and it can also be used to help commence treatment. Exudates in the retina are what cause diabetic retinopathy to develop, which happens when blood vessels in the retina leak fluid into the retina itself. As a consequence of this, a diabetic patient runs the risk of losing their sight. Microaneurysms and haemorrhages may occasionally cause patients suffering from DR to experience a loss of vision. The process through which the retina neovascularizes, or sprouts new blood vessels, accelerates along with the progression of vision loss [37]. Finding blood vessels in fundus pictures requires a number of processes to be completed. The technique may be shown in figure 7 which can be seen below.

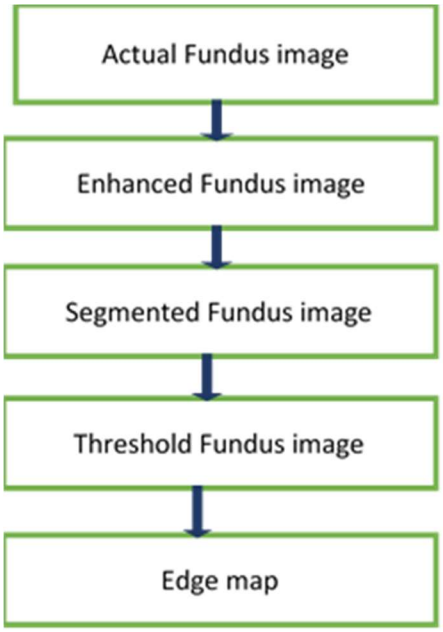

Figure7. Stages of blood vessel extraction

The period of preparation begins first, then the actual process of segmentation takes place. During this process, the basic picture stored in the retina undergoes a transformation into a more refined image. Before beginning the segmentation procedure, preprocessing has to be finished. During the processing stage, the image will have any noise or uneven lighting that may have been present corrected. The picture is acquired in a superior condition once the preprocessing step is completed. After that, several applications of the segmentation approach are tried out on the picture. The use of the threshold will result in the creation of a binary map of the blood vessels. Post processing is the term given to the process of removing unwanted or inaccurate pixels from an image.

According to the author of [38], there are two distinct categories that can be used to categorise the procedures that are used for detecting and segmenting retinal blood vessels. These categories may be used interchangeably.

1) Methods that rely on human intervention, and 2) procedures that are derived from established guidelines. When using a supervised method to analyse the data, the first step in computing the spectrum is to apply an algorithm to a picture in order to determine the information class contained within it. The provided method is used to the original photographs that were taken in order to classify the image's pixel data during this process. These photographs were taken at the beginning. The following table provides excerpts from a variety of algorithms that might be used in the process of identifying and classifying blood vessels.

Table2. Detection and Segmentation algorithms

Author	Database	Segmentation	Classifier	Result
Xu Li et al., (2010) [39]	DERIVE	Sobel filter for OD, Adaptive	Large and small blood vessels,	acc.= 93.36% , sen. = 85.57%

		threshold,	SVM,	
D Martin et al., (2011) [40]	DRIVE, STARE	grey level features	ANN	acc.= 95.26%, sen.= 69. 44%, sp.= 98.19%
M M Fraz et al., (2012) [41]	DRIVE, STARE	Mathematical morphology, aggregation operators	Large and thin blood vessels,	acc.= 95.52% Sp. = 97.23
T.V Yuen et al., (2013) [42]	STARE, DRIVE	Linear combination of line response	Blood Vesel, SVM	acc.= 93.24%, 94.07%
S E Rajan et al., (2014) [43]	DRIVE	SIFT	Blood Vessel	Acc= 92.1%
L Zhang et al., (2015) [44]	DERIVE	KNN	Blood Vessel	acc.= 95.05% , sen.= 78.12%, sp.= 96.62%
R G Ramana et al., (2016) [45]	DERIVE	Gabour filters, PCA	Blood vessels, Root guided tree,	acc.= 95.36% , sen. = 70.79%, sp.= 97.78%
J P Dash et al., (2017) [46]	DERIVE, CHASED B1	difference of binary and enhanced image	Blood vessels	Acc= 95.9
M Hasan et al., (2017) [47]	HMM, OR	HMM, OR	Blood Vessels	Acc= 95.7, sen.= 81.0% sp.= 97.0%
Soorya M et al., (2018) [48]	VEIR	Iterative process, bend points detection as countour of OD	Glaucoma	Acc=97.01%

C. Techniques of MAs &HMs Detection

There are two separate approaches to taking use of automated analysis for detecting microaneurysms and DR development. Image analysis that is based on a road map is one of the methods that may be used to identify changes in microaneurysms. Methods of statistical analysis and pattern categorization are used in the second technique, which focuses on researching the features of the illness. Furthermore, it has been shown that pathological risk factors have a role in the recurrence of microaneurysms (MA) [38]. [Citation needed]

The author of [49] presents a method for locating micro aneurysms as well as a system for categorising them by making use of filter banks to recognise DR and related lesions. Both of these methods can be found in the same reference. This process may be broken down into three distinct stages. In the first stage, which is known as "feature extraction," fundus photos are examined in order to search for possible sites of microaneurysms. Both GMM and SVM classifiers were used

to sort the recovered features into several categories in order to get the best possible outcomes. Several different methods of image analysis that have the potential to detect DR in its earliest stages have been offered. According to the findings of this study [50], photographs of the retina have the potential to be used in the process of identifying different stages of DR in addition to a number of disorders, such as microaneurysms, exudates, and haemorrhages. [Citation needed] The discovery of haemorrhages and blood vessels, in addition to the categorization of diabetic retinopathy into severe, moderate, mild, and normal types, called for the development of cutting-edge diagnostic tools and automated systems. In the beginning, color-based segmentation as well as the colour contrast of the retina's blood vessels were employed in order to find the retina's blood vessels. In order to locate haemorrhages, a number of different procedures, such as density analysis and bounding box analysis, were developed. Following this step, the random forest approach is used in order to classify the haemorrhages and retinal blood vessels [51].

Table3. Different methods for detection of DR features

Author	Database	Pre-processing and Classifier	Features
G. Quellec et al., (2011)[52]	DRIVE	Treshold method, mathematical morphology	MAs
M. Usman Akram et al., (2012) [53]	DIARETDB0,DIARETDB1	Mathematical morphology, gabour filter, geometrical and statistical features	MAs, HMAS
N S Datta et al., (2013) [54]	STARE	Median, CLAHE and canny edge detection, Morphological and logical operators	MAs
X W Zhand et al., (2014) [55]	E OPHTHA, DIARETDBI	Morphological inpainting, template matching, mathematical morphology	Exudates
G. Leontidis et al.,(2015) [56]	Real data	widths, angles, branching coefficient (BC), angle-to- BC ratio and statistical features	Biomarkers for DR

E Imani et al., (2016) [57]	DiaretDB, HEI-MED, E OPHTHA	Mathematical morphology, shearlet transformation, non subsampled contourlet transformation	Exudates
J Amin et al., (2017) [58]	HRIS,DERIVE, VDIS, HRF, MESSIDOR, DIARTDB1	Gabour filter, geometric features	Exudates
M M Fraz et al., (2017) [59]	DIARETDB1, HEI-MED, E-OPTHIA	Mean filter, Mathematical morphology	Exudates
J Kaur et al., (2018) [60]	STARE, MESSIDOR, DIARETDB1	Two pass filter, calculus, Laplace filter and high pass filter, matching filter	Exudates
J I Orlando et al., (2018) [61]	E OPHTHA, DIARETDB1, MESSIDOR	interpolation, gaussian filter, Mathematical morphology	Red Lesion

D. Techniques of exudates detection

In relation to this, [62] provided the results of research on the classification of DR lesions by the use of artificial neural networks (ANN). Lesions, such as microaneurysms, exudates, and blood vessels, are categorised, along with the grade and stage of the disorders, with the use of retinal imaging. The author of [63] describes a one-of-a-kind approach for automatically categorising diabetic retinopathy and retinal lesions using fundus images. This method is touted as being "unique." The bifurcation point, the exudate area, the non-segmented texture, and the blood vessel area were used to extract feature characteristics, which were then used to construct this report. An automated method for DR identification was proposed by the author of [64], and an ANN classifier was used to characterise the lesions that were brought on by DR. When using fundus imaging, a number of different lesions, such as microaneurysms, exudates, homogeneity, and blood vessels, may be seen.

5. Conclusion

The most common cause of vision loss that is permanent, diabetic retinopathy, may be detected early and treated, which can help avoid further vision loss (DR). Patients living with diabetes who put off getting treatment for diabetic retinopathy are at risk of experiencing damage to the retina, which is the lining of the back of the eye that detects light (DR). Diabetes retinopathy (DR) is a significant obstacle for diabetics since it puts their vision in jeopardy. It is the most important factor in determining whether or not a person would get diabetes when they are of working age. If we search for exudates, microaneurysms, and haemorrhages in that region, we may be able to locate the DR more quickly. Because of this, we are now in a position to classify photographs as having either mild, moderate, or severe diabetic retinopathy. This paper demonstrates the relevance

of algorithmic development for detection and algorithmic classification, which is an important application of algorithmic development. It has been shown that feature extraction is also very important. The findings of an inquiry carried out by the writers into the diagnosis of diabetic retinopathy are presented and discussed in this article. The results of this study would be useful to academics and technical specialists who are required to employ the most recent research in this subject. Image preprocessing on medical images is an area that needs a great deal of research because of the significant role it plays in the accurate identification of diabetes features in the algorithms that are used for diabetic screening.

References

[1] T. Kauppi, V. Kalesnykiene, J.-K. Kamarainen et al., "The DIARETDB1 diabetic retinopathy database and evaluation protocol," in *Proceedings of the 18th British Machine Vision Conference(BMVC '07)*, pp. 15.1–15.10, September 2007.

[2] D. Kayal and S. Banerjee, "A new dynamic thresholding based technique for detection of hard exudates in digital retinal fundus image," in *Proceedings of the 1st International Conferenceon Signal Processing and Integrated Networks (SPIN '14)*, pp. 141–144, February 2014.

[3] C. Agurto, V. Murray, E. Barriga et al., "Multiscale AM-FM methods for diabetic retinopathy lesion detection," *IEEE Transactionson Medical Imaging*, vol. 29, no. 2, pp. 502–512, 2010.

[4] G. Mahendran, R. Dhanasekaran, and K. N. Narmadha Devi, "Identification of exudates for Diabetic Retinopathy based on morphological process and PNN classifier," in *Proceedings ofthe 3rd International Conference on Communication and SignalProcessing (ICCSP '14)*, pp. 1117–1121, IEEE, Melmaruvathur, India, April 2014.

[5] C. Agurto, V. Murray, H. Yu et al., "A multiscale optimization approach to detect exudates in the macula," *IEEE Journal ofBiomedical and Health Informatics*, vol. 18, no. 4, pp. 1328–1336, 2014.

[6] A. F. Aqeel and S. Ganesan, "Automated algorithm for retinal image exudates and drusens detection, segmentation, and measurement," in *Proceedings of the IEEE International Conferenceon Electro/Information Technology (EIT '14)*, pp. 206–215, Milwaukee,Wis, USA, June 2014.

[7] P. M. Rokade and R. R. Manza, "Automatic detection of hard exudates in retinal images using haar wavelet transform," *International Journal of Application or Innovation in Engineering& Management*, vol. 4, no. 5, pp. 402–410, 2015.

[8] https://www.mayoclinic.org/diseases-conditions/diabetic-retinopathy/symptoms-causes/syc-20371611.

[9] J.Krause,V.Gulshan,E.Rahimy,P.Karth,K.Widner,G.S.Corrado,L. Peng, and D. R. Webster, ''Grader variability and the importance of reference standards for evaluating machine learning models for diabetic retinopathy,'' Ophthalmology, vol. 125, no. 8, pp. 1264–1272, Aug.2018

[10] P. Vashist, N. Gupta, S. Singh, and R. Saxena, ``Role of early screening for diabetic retinopathy in patients with diabetes mellitus: An overview," Indian J. Community Med., Off. Publication Indian Assoc. Preventive Social Med., vol. 36, no. 4, p. 247, 2011.

[11] X. Li, X. Hu, L. Yu, L. Zhu, C. Fu and P. Heng, "CANet: Cross-Disease Attention Network for Joint Diabetic Retinopathy and Diabetic Macular Edema Grading," in IEEE Transactions on Medical Imaging, vol. 39, no. 5, pp. 1483-1493, May 2020, doi: 10.1109/TMI.2019.2951844.
[12] L. Qiao, Y. Zhu and H. Zhou, "Diabetic Retinopathy Detection Using Prognosis of Microaneurysm and Early Diagnosis System for Non-Proliferative Diabetic Retinopathy Based on Deep Learning Algorithms," in IEEE Access, vol. 8, pp. 104292-104302, 2020, doi: 10.1109/ACCESS.2020.2993937.
[13] E. V. Carrera, A. González and R. Carrera, "Automated detection of diabetic retinopathy using SVM," 2017 IEEE XXIV International Conference on Electronics, Electrical Engineering and Computing (INTERCON), Cusco, 2017, pp. 1-4, doi: 10.1109/INTERCON.2017.8079692.
[14] Ö. Deperlıoğlu and U. Köse, "Diagnosis of Diabetic Retinopathy by Using Image Processing and Convolutional Neural Network," 2018 2nd International Symposium on Multidisciplinary Studies and Innovative Technologies (ISMSIT), Ankara, 2018, pp. 1-5, doi: 10.1109/ISMSIT.2018.8567055.
[15] S. Kimpan, N. Maneerat and C. Kimpan, "Diabetic retinopathy image analysis using radial inverse force histograms," 2017 International Conference on Intelligent Informatics and Biomedical Sciences (ICIIBMS), Okinawa, 2017, pp. 266-271.
[16] Shikhar Seth &BasantAgarwal (2018) A hybrid deep learning model for detecting diabetic retinopathy, Journal of Statistics and Management Systems, 21:4, 569-574.
[17] A. ElTanboly, M. Ghazaf, A. Khalil, A. Shalaby, A. Mahmoud, A. Switala, M. El-Azab, S. Schaal, and A. El-Baz, ``An integrated framework for automatic clinical assessment of diabetic retinopathy grade using spectral domain OCT images," in Proc. IEEE 15th Int. Symp. Biomed.Imag.(ISBI), Apr. 2018, pp. 1431_1435.
[18] Y.-H. Li, N.-N.Yeh, S.-J.Chen, and Y.-C. Chung, ``Computer-assisted diagnosis for diabetic retinopathy based on fundus images using deep convolutional neural network," Mobile Inf. Syst., vol. 2019, pp. 1_14, Jan. 2019.
[19] X. Li, T. Pang, B. Xiong, W. Liu, P. Liang and T. Wang, "Convolutional neural networks based transfer learning for diabetic retinopathy fundus image classification," 2017 10th International Congress on Image and Signal Processing, BioMedical Engineering and Informatics (CISP-BMEI), Shanghai, 2017, pp. 1-11, doi: 10.1109/CISP-BMEI.2017.8301998.
[20] L. Zhou, Y. Zhao, J. Yang, Q. Yu, and X. Xu, ``Deep multiple instance learning for automatic detection of diabetic retinopathy in retinal images," IET Image Process., vol. 12, no. 4, pp. 563_571, 2017.
[21] S. Suriyal, C. Druzgalski and K. Gautam, "Mobile assisted diabetic retinopathy detection using deep neural network," 2018 Global Medical Engineering Physics Exchanges/Pan American Health Care Exchanges (GMEPE/PAHCE), Porto, 2018, pp. 1-4, doi: 10.1109/GMEPE-PAHCE.2018.8400760.
[22] V. Gulshan, L. Peng, M. Coram, M. C. Stumpe, D. Wu,A. Narayanaswamy, S. Venugopalan, K.Widner, T. Madams, J. Cuadros,R. Kim, R. Raman, P. C. Nelson, J. L. Mega, and D. R.

Webster,``Development and validation of a deep learning algorithm for detectionof diabetic retinopathy in retinal fundus photographs," JAMA, vol. 316,no. 22, pp. 2402_2410, Dec. 2016.
[23] T. Bui, N. Maneerat and U. Watchareeruetai, "Detection of cotton wool for diabetic retinopathy analysis using neural network," 2017 IEEE 10th International Workshop on Computational Intelligence and Applications (IWCIA), Hiroshima, 2017, pp. 203-206.
[24] P. Nijalingappa and B. Sandeep, "Machine learning approach for the identification of diabetes retinopathy and its stages," 2015 International Conference on Applied and Theoretical Computing and Communication Technology (iCATccT), Davangere, 2015, pp. 653-658.
[25] W. Kusakunniran, Q. Wu, P. Ritthipravat, and J. Zhang, ``Hard exudates segmentation based on learned initial seeds and iterative graph cut," Comput. Methods Programs Biomed., vol. 158, pp. 173183, May 2018.
[26] J. Mo and L. Zhang, ``Multi-level deep supervised networks for retinal vessel egmentation," Int. J. Comput. Assist. Radiol. Surg., vol. 12, no. 12,Drpp. 21812193, Dec. 2017.
[27] S. Wang, Y. Yin, G. Cao, B. Wei, Y. Zheng, and G. Yang, ``Hierarchical retinal blood vessel segmentation based on feature and ensemble learning," Neurocomputing, vol. 149, pp. 708717, Feb. 2015.
[28] M. D. Abràmoff, Y. Lou, A. Erginay, W. Clarida, R. Amelon, J. C. Folk, and M. Niemeijer,``Improved automated detection of diabetic retinopathy on a publicly available dataset through integration of deep learning," Investigative Opthalmol. Vis. Sci., vol. 57, no. 13, pp. 52005206, Oct. 2016.
[29] P. Chudzik, S. Majumdar, F. Calivá, B. Al-Diri, and A. Hunter, ``Microaneurysm detection using fully convolutional neural networks," Comput. Methods Programs Biomed., vol. 158, pp. 185-192, May 2018.
[30] Q. Abbas, I. Fondon, A. Sarmiento, S. Jiménez, and P. Alemany, ``Automatic recognition of severity level for diagnosis of diabetic retinopathy using deep visual features," Med. Biol. Eng. Comput., vol. 55, no. 11, pp. 19591974, Nov. 2017.
[31] S. A. G. Naqvi, M. F. Zafar, and I. U. Haq, ``Referral system for hard exudates in eye fundus," Comput. Biol. Med., vol. 64, pp. 217-235, Sep. 2015.
[32] R. Arunkumar and P. Karthigaikumar, ``Multi-retinal disease classifcation by reduced deep learning features," Neural Comput. Appl., vol. 28, no. 2, pp. 329-334, Feb. 2017.
[33] Early Treatment Diabetic Retinopathy Study Research Group, ‘‘Grad- ing diabetic retinopathy from stereoscopic color fundus photographs— An extension of the modified Airlie House classification: ETDRS report number 10,’’ Ophthalmology, vol. 98, pp. 786–806, May1991
[34] S. S. Kar and S. P. Maity, "Automatic Detection of Retinal Lesions for Screening of Diabetic Retinopathy," in IEEE Transactions on Biomedical Engineering, vol. 65, no. 3, pp. 608-618, March 2018.
[35] S. H. Bhat and P. Kumar, ‘‘Segmentation of optic disc by localized active contour model in retinal fundus image,’’ in Smart Innovations in Communication and Computational Sciences. Springer, 2019, pp. 35–44.

[36] S. Roychowdhury, D. D. Koozekanani, S. N. Kuchinka, and K. K. Parhi, ‘‘Optic disc boundary and vessel origin segmentation of fundus images,’’ *IEEE J. Biomed. Health Informat.*, vol. 20, no.6, pp. 1562–1574, Nov. 2016.
[37] M.I Khan et. al, “A Review of Retinal Vessel Segmentation Techniques And Algorithms”,Int. J. Comp. Tech. Appl., Vol 2, no. 5, pp 1140-1144, Sep-Oct, 2011.
[38] J. Xu et al., "Automatic Analysis of Microaneurysms Turnover to Diagnose the Progression of Diabetic Retinopathy," in IEEE Access, vol. 6, pp. 9632-9642, 2018.
[39] Xu Shuqian Luo Lili. A novel method for blood vessel detection from retinalimages. BioMed Eng OnLine 2010;9:14.
[40] Marin D, Aquino A, Gegundez-Arias ME, Bravo JM. A new supervised method for blood vessel segmentation in retinal images by using gray-level and moment invariants- based features. IEEE Trans. Med. Imaging 2011 Jan;30(1):146–58.
[41] Fraz MM, Barman SA, Remagnino P, Hoppe A, Basit A, Uyyanonvara B, Rudnicka AR, Owen CG. An approach to localize the retinal blood vessels using bit planes and centerline detection. Comput Methods Programs Biomed 2012;108(2):600–16.
[42] Nguyen Uyen TV, Bhuiyan Alauddin, Park Laurence AF, Ramamohanarao Kotagiri. An effective retinal blood vessel segmentation method using multi-scale line detection. Pattern Recogn 2013;46(3):703–15.
[43] Wilfred Franklin S, Rajan Edward S. Retinal vessel segmentation employing ann technique by gabor and moment invariants-based features. Appl Soft Comput 2014;22(Supplement C):94–100.
[44] Zhang Lei, Fisher Mark, Wang Wenjia. Retinal vessel segmentation using multiscale textons derived from keypoints. Comput Med Imaging Graphics 2015;45(Supplement C):47–56.
[45] GeethaRamani R, Balasubramanian Lakshmi. Retinal blood vessel segmentation employing image processing and data mining techniques for computerized retinal image analysis. Biocybernet Biomed Eng 2016;36(1):102–18.
[46] Dash Jyotiprava, Bhoi Nilamani. A thresholding based technique to extract retinal blood vessels from fundus images. Future Comput Inform J 2017;2(2):103–9.
[47] Hassan Mehdi, Muhammad Amin, Murtza Iqbal, Khan Asifullah, Chaudhry Asmatullah. Robust hidden markov model based intelligent blood vessel detection of fundus images. Comput Methods Programs Biomed 2017;151(Supplement C):193–201.
[48] Soorya M, Issac Ashish, Dutta Malay Kishore. An automated and robust image processing algorithm for glaucoma diagnosis from fundus images using novel blood vessel tracking and bend point detection. Int J Med Inform 2018;110:52–70.
[49] M. U. Akram, S. Khalid, and S. A. Khan, ‘‘Identification and classifi- cation of microaneurysms for early detection of diabetic retinopathy,’’ Pattern Recognit., vol. 46, no. 1, pp. 107–116, Jan.2013.
[50] N. Singh and R. C. Tripathi, ‘‘Automated early detection of diabetic retinopathy using image analysis techniques,’’ Int. J. Comput.Appl., vol. 8, no. 2, pp. 18–23,2010

[51] K. Verma, P. Deep, and A. G. Ramakrishnan, ‘‘Detection and classifica- tion of diabetic retinopathy using retinal images,’’ in Proc. Annu.IEEE India Conf., Dec. 2011, pp.1–6
[52] Quellec G, Russell SR, Abramoff MD. Optimal filter framework for automated, instantaneous detection of lesions in retinal images. IEEE Trans Med Imaging 2011 Feb;30(2):523–33
[53] Usman Akram M, Khalid Shehzad, Khan Shoab A. Identification and classification of microaneurysms for early detection of diabetic retinopathy. Pattern Recogn 2013 January;46(1):107–16.
[54] Datta Niladri Sekhar, Dutta Himadri Sekhar, De Mallika, Mondal Saurajeet. An effective approach: Image quality enhancement for microaneurysms detection of non-dilated retinal fundus image. Procedia Technol 2013;10(Supplement C):731–7.
[55] Zhang Xiwei, Thibault Guillaume, Decenciere Etienne, Marcotegui Beatriz, La Bruno. Exudate detection in color retinal images for mass screening of diabeticretinopathy. Med Image Anal 2014;18(7):1026–43.
[56] Leontidis G, Al-Diri B, Wigdahl J, Hunter A. Evaluation of geometric features as biomarkers of diabetic retinopathy for characterizing the retinal vascular changes during the progression of diabetes. 2015 37th Annual International Conference of the IEEE Engineering in Medicine and Biology Society (EMBC), Aug 2015:5255–9.
[57] Imani Elaheh, Pourreza Hamid-Reza. A novel method for retinal exudate segmentation using signal separation algorithm. Comput Methods Programs Biomed 2016;133:195–205.
[58] Amin Javeria, Sharif Muhammad, Yasmin Mussarat, Ali Hussam, Fernandes Steven Lawrence. A method for the detection and classification of diabetic retinopathy using structural predictors of bright lesions. J Comput Sci 2017;19:153–64.
[59] Joel EW, Koh U, Acharya Rajendra, Hagiwara Yuki, Raghavendra U, Jen Hong Tan S, Sree Vinitha, Sulatha V, Bhandary A, Rao Krishna, Sivaprasad Sobha, Chua Kuang Chua, Laude Augustinus, Tong Louis. Diagnosis of retinal health in digitalfundus images using continuous wavelet transform (cwt) and entropies. Comput Biol Med 2017 May;84(C):89–97.
[60] Jaskirat Kaur, Mittal Deepti. A generalized method for the segmentation of exudates from pathological retinal fundus images. Biocybernet Biomed Eng 2018;38(1):27–53.
[61] Orlando Jose Ignacio, Prokofyeva Elena, del Fresno Mariana, Blaschko Matthew B. An ensemble deep learning based approach for red lesion detection in fundus images. Comput Methods Progr Biomed 2018;153(Supplement C):115–27.
[62] M.P. Paing, S. Choomchuay, and M. D. R. Yodprom, ‘‘Detection of lesions and classification of diabetic retinopathy using fundus images,’’ in Proc. 9th Biomed. Eng. Int. Conf. (BMEiCON), Dec. 2016, pp.1–5.
[63] M. Purandare and K. Noronha, ‘‘Hybrid system for automatic classifica- tion of diabetic retinopathy using fundus images,’’ in Proc. Online Int. Conf. Green Eng. Technol. (IC-GET), Nov. 2016, pp.1–5.
[64] E. M. Shahin, T. E. Taha, W. Al-Nuaimy, S. El Rabaie, O. F. Zahran, andF. E. A. El-Samie, ‘‘Automated detection of diabetic retinopathy in blurred digital fundus images,’’ in Proc. 8th Int. Comput.Eng. Conf. (ICENCO), Dec. 2012, pp.20–25.